

editorial & views

Congenital dyserythropoietic anemias: a still unsolved puzzle

Achille Iolascon 673-674

original papers

Intracellular cytokine profile of cord blood T_H1 and NK- cells and monocytes

Mauro Krampera, Luisa Tavecchia, Fabio Benedetti,
Gianpaolo Nadali, Giovanni Pizzolo 675-679

A comparative evaluation of gene transfer into blood cells using the same retroviral backbone for independent expression of the EGFP and Δ LNFR marker genes

Ilaria Giaretta, Domenico Madeo, Roberta Bonaguro,
Antonio Cappellari, Francesco Rodeghiero,
Giorgio Palù 680-689

Fetal and embryonic hemoglobins in erythroblasts of chromosomally normal and abnormal fetuses at 10-40 weeks of gestation

Raghad Al-Mufti, Henry Hambley, Farzin Farzaneh,
Kypros H. Nicolaidis 690-693

Folate status in Italian blood donors: relation to gender and smoking

Arturo Cafolla, Francesco Dragoni, Gabriella Girelli,
Maria Elena Tosti, Alessandro Costante, Donatella
Pastorelli, Giorgio Bedogni, Steve Scott 694-698

Relevance of presenting white blood cell count and kinetics of molecular remission in the prognosis of acute myeloid leukemia with CBF β /MYH11 rearrangement

Guillermo Martín, Eva Barragán, Pascual Bolufer,
Carmen Chillón, Ramón García-Sanz, Teresa Gómez,
Salut Brunet, Marcos González, Miguel A. Sanz 699-703

Combined use of reverse transcriptase polymerase chain reaction and flow cytometry to study minimal residual disease in Philadelphia positive acute lymphoblastic leukemia

Luz Muñoz, Olga López, Rodrigo Martino, Salut Brunet,
Mar Bellido, Enriqueta Rubiol, Jorge Sierra,
Josep F. Nomdedéu 704-710

Clinical significance of P-glycoprotein expression and function for response to induction chemotherapy, relapse rate and overall survival in acute leukemia

Christian Wuchter, Leonid Karawajew, Velia Ruppert,
Martin Schrappe, Thomas Büchner, Claudia Schoch,
Torsten Haferlach, Jochen Harbott, Richard Ratei,
Bernd Dörken, Wolf-Dieter Ludwig 711-721

Lomustine and melphalan cannot be replaced by cyclophosphamide and etoposide without reducing efficacy in MOPPEBVCAD chemotherapy for advanced Hodgkin's disease

Paolo G. Gobbi, Chiara Brogna, Raffaella Bertè, Maria Pia
Petrilli, Stefano Molica, Francesco Angrilli, Emilio Iannitto,
Maria Laura Ghirardelli, Nicola Di Renzo, Luigi Cavanna,
Edoardo Ascari for the GISL
(Gruppo Italiano Studio Linfomi) 722-728

Efficacy of the VBM regimen in the treatment of elderly patients with Hodgkin's disease

Pier Luigi Zinzani, Massimo Magagnoli, Maurizio
Bendandi, Enza Barbieri, Andrea Galuppi, Filippo
Gherlinzoni, Monica Tani, Patrizia Albertini, Vittorio
Stefoni, Lucio Babini, Sante Tura 729-732

Patient management strategies and transplantation techniques in European stem cell transplantation centers offering breast cancer patients high-dose chemotherapy with peripheral blood stem cell support: a joint report from the EORTC and EBMT

Niels Neymark, Giovanni Rosti 733-744

Computed tomographic scan of the chest, latex agglutination test and plasma (1 \rightarrow 3)-beta-D-glucan assay in early diagnosis of invasive pulmonary aspergillosis: a prospective study of 215 patients

Masahiro Kami, Yuji Tanaka, Yoshinobu Kanda,
Seishi Ogawa, Tomohiko Masumoto, Kuni Ohtomo,
Tomoko Matsumura, Toshiki Saito, Utako Machida,
Takeshi Kashima, Hisamaru Hirai 745-752

trends in hematology

Congenital dyserythropoietic anemia type III

Herbert Sandström, Anders Wahlin 753-757

case of the month

Cutaneous promyelocytic sarcoma at sites of vascular access and marrow aspiration.

A characteristic localization of chloromas in acute promyelocytic leukemia?

Miguel A. Sanz, Luis Larrea, Guillermo F. Sanz,
Guillermo Martín, Amparo Sempere, Federico Gomis,
Jesús A. Martínez, Anabel Regadera, Silvana Saavedra,
Isidro Jarque, Carmen Jiménez, José Cervera,
Javier de la Rubia 758-762

the irreplaceable image

Granulocytic sarcoma in a non-leukemic patient presenting with an unusual cutaneous paraneoplastic syndrome

Luigi Iuliano, Angela Gurgo, Stefano Licci 763

Avid ⁶⁷Ga uptake in multiple myeloma relapsing after bone marrow transplant

Gennaro De Rosa, Luca Pezzullo,
Silvana Del Vecchio 764

scientific correspondence

Dihydrofolate reductase activity in the erythro- blasts of patients with 5q- syndrome

Rosanna Nano, Rosangela Invernizzi, Alessandro Pecci,
Monica Civallero, Giuseppe Gerzeli 765-766

Beneficial effect of low dose G-CSF and cyclosporin-A in a case of chronic neutropenia

Vincenzo Martinelli, Mario Volpicelli, Fabrizio Pane,
Laura Ciccoira, Bruno Rotoli 766-767

2000
vol. 85
no. 7

CONTENTS
(indexed by
Current
Contents/Life
Sciences and
in Faxon
Finder and
Faxon
XPRESS,
also available
on diskette
with
abstracts)

Translocation (15;17)(q22;q21) not associated with acute promyelocytic leukemia and negative for PML/RAR α rearrangement
Edmond Shiu Kwan Ma, Wing Yan Au,
Thomas Shek Kong Wan, Yok Lam Kwong,
Li Chong Chan 768-769

Lung toxicity following fludarabine, cytosine arabinoside and mitoxantrone (FLAN) treatment for acute leukemia
Marzia Salvucci, Roberto Zanchini, Anna Lia Molinari,
Eliana Zuffa, Venerino Poletti, Giovanni Poletti,
Alfonso Zaccaria 769-770

Difficulties in the diagnosis of primary cardiac lymphomas
Paolo Carfagna, Alessandra Redondi, Fabrizio Taglietti,
Mario Armando Battista, Giulia d'Amati,
Camillo Brandimarte 770-772

Gallium-67 uptake by cutaneous lesions in a patient with Burkitt-like non-Hodgkin's lymphoma
Gloria Ruiz-Hernández, Antonio Gutiérrez-García,
Javier García-Conde 772

Simultaneous occurrence of multiple myeloma and Hodgkin's disease. A case report
Chrisavgi Lalayanni, Stamatia Theodoridou,
Anastasia Athanasiadou, Riad Saloum,
Costantinos Tsatalas 772-773

Demonstration of Epstein-Barr virus in a case of multiple myeloma after renal transplantation
Idoya Ancín, Josep Sarrá, Juan Peris, Vicente Romagosa,
Alicia Domingo-Claros, Alberto Grañena 773-774

A new case of Sézary cell leukemia: a morphologic variant of prolymphocytic leukemia
M^a Encarnación Pérez-Vila, Blanca Espinet,
Francesc Solé, Carme Pedro, Soledad Woessner,
Lourdes Florensa 775-776

Modifications of lymphocyte subsets in patients with autoimmune thrombocytopenic purpura submitted to splenectomy
Maria Gabriella Mazzucconi, Paola Piola,
Maria Cristina Arista, Laura Bizzoni, Anna Antenucci,
Laura Conti 776-777

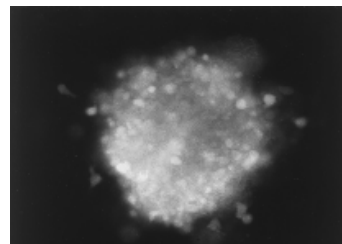
Abnormal bleeding in a patient with chronic lymphocytic leukemia and acute hepatitis due to a circulating heparin-like anticoagulant
Pilar Llamas, Elena Prieto, Alejandro Román, José Espinoza, Carlos Soto, José Fracisco Tomás . . 777-778

Effect of oral anticoagulant therapy on fibrinolysis parameters in chronic non-rheumatic atrial fibrillation
Vanessa Roldán-Schilling, Francisco Marín-Ortuño,
Pascual Marco-Vera, Francisco Sogorb-Garri . . 778-780

Donor lymphocyte infusion for post-transplant relapse of Hodgkin's lymphoma
Gennaro De Rosa, Luca Pezzullo, Nicola Scarpato,
Carmine Selleri, Anna Lucania, Bruno Rotoli . . . 780-781

Severe disseminated toxoplasmosis after unrelated bone marrow transplantation: a case report
Daniela V. Longoni, Roberto Fumagalli, Monica Fumagalli, Anna Cappellini, Cornelio Uderzo . . . 781-782

Immunologic short term reconstitution after tandem unselected peripheral blood progenitor cell transplantation for multiple myeloma
Luca Laurenti, Simona Sica, Silvia Cicconi,
Patrizia Chiusolo, Nicola Piccirillo,
Giuseppe Leone 782-784



On the cover. Fluorescence microscopic image of a representative EGFP+BFU-E methylcellulose colony (see p. 686).